UNIVERSITY OF ARKANSAS

COLLEGE OF AGRICULTURE

Agricultural Experiment Station

STUDIES ON THE HEMATOLOGY OF NORMAL AND CHOLERA-INFECTED HOGS

BULLETIN No. 120

(TECHNICAL)

FAYETTEVILLE, ARKANSAS

OCTOBER, 1914

The Bulletins of this Station are sent free to all residents of the State who request them.

UNIVERSITY OF ARKANSAS
AGRICULTURAL EXPERIMENT STATION

BOARD OF TRUSTEES

His Excellency, George W. Hays, *Chairman.*

Hon. W. H. Askew,
Hon. H. L. Ponder,
Hon. Frank Pace,
Hon. Geo. B. Cook,
Hon. Charles Richardson,
Hon. A. B. Banks,
Hon. J. D. Head,
Hon. T. A. Turner,
Hon. W. H. Cravens, *Secretary.*

BOARD OF CONTROL

Committee on Agricultural College, President of the University, *Director of the Station.*

STATION STAFF

Martin Nelson.....................Director of the Experiment Station
Director of Extension
R. R. Dinwiddie.........................Pathologist and Bacteriologist
J. L. Hewitt...Plant Pathologist
R. C. Thompson..................................Agricultural Chemist
G. G. Becker...Entomologist
R. M. Gow..Veterinarian
W. R. Wheelock...Extension
W. L. Fowler....................................Animal Husbandman
Sarah Pettit..Home Economics
W. C. Lassetter...Agronomist
C. W. Watson*.................................Farm Demonstration
C. V. Ruzek....................................Assistant Agronomist
J. M. Borders..................................Assistant in Extension
J. R. Tucker.....................................Assistant Chemist
H. E. Truax.................................Assistant Horticulturist
L. W. Osborn...................................Assistant Agronomist
W. S. Fields...............................Assistant Plant Pathologist
C. L. McArthur................Assistant Pathologist and Bacteriologist
D. H. Branson...........................Assistant Animal Husbandman
J. S. Knox......................................Assistant Horticulturist
M. S. Baker....................................Assistant Agronomist
Marcella Arthur..................................Home Economics
C. D. Stubbs...................................Assistant Veterinarian
E. Kilpatrick....................................Assistant Agronomist
Mary Elizabeth Metzger.............................Home Economics
W. J. Jernigan*..Club Work
Emma Archer*.......................................Girls' Club Work
J. C. Barnett*.....................................Farm Demonstration
R. C. Davidson*.................................Farm Demonstration
H. F. Kapp*.......................................Farm Demonstration
W. A. Denman....................Vet. Dept., Agent in Tick Eradication

*In cooperation with United States Department of Agriculture.

Correspondents should notify the Director of any change in Post Office ***address, or failure or delay in receiving bulletins.***

MARTIN NELSON, ***Director,***

Fayetteville, Arkansas.

STUDIES ON THE HEMATOLOGY OF NORMAL AND CHOLERA INFECTED HOGS.

R. R. DINWIDDIE.

In the scientific study of hog cholera, whether by investigations of farm outbreaks or by experimental methods, a serious bar to further advancement is the lack of any specific test or reaction on which an exact diagnosis can be based. Our knowledge in individual cases or even in farm outbreaks as a whole, that particular changes observed are the effect of cholera infection, is based upon a collection of anatomical lesions none of which singly can be said to be pathognomonic of this disease even when present, and many of which, in a considerable percentage of cases, may be absent.

It is known that in hog cholera the virus (invisible or as yet unseen) is disseminated in the blood and, as I have shown in a previous report,* in some way intimately associated with the blood corpuscles. It was shown that removal (or infinitesimal dilution) of the plasma of citrated blood or the serum of defibrinated blood of cholera diseased hogs by repeated centrifugal washings with isotonic salt solution in no degree lessens the virulence of the remaining component, the blood corpuscles. As long as these are intact (unlaked) they apparently retain a residuum of virus inseparable by the washing process.

I have interpreted this as implying an intracorpuscular habitat of the ultimate infective particle or entity of the disease although it is equally conceivable but less in line with what we know of other blood infections that it may be epicorpuscular, attached to the surface of the corpuscles.

This evident relation of the hog cholera virus to the corpuscular elements of the blood led me to undertake a closer microscopic study of the blood of normal and cholera infected pigs in the hope that something further might be learned which would prove of diagnostic or perhaps etiologic significance.

Methods. For examination of fresh or "living" blood the ear or tail from which the hair had previously been removed by clipping or shaving was thoroughly cleansed and washed with alcohol and the blood made to flow by snipping off a piece of the tissue with sharp scissors, or, occasionally, by puncture of a vein of the ear with a needle. A small drop was transferred on the corner of a piece of clean

*Bulletin No. 111, Arkansas Agricultural Experiment Station.

card or a cover glass to the center of a slide and this at once covered by another cover glass. If both slide and cover glass are clean a thin layer of unchanged corpuscles is secured. Several attempts may be needed before a satisfactory preparation is obtained. The edges are at once sealed with vaseline. Such preparations are suitable for examination by transmitted or dark field illumination only when the erithrocytes are found to lie separate from each other and free from crenation or distortion. In the laboratory there is no difficulty about this, but in making preparations from the larger animals many will be found unsuitable.

In pigs suffering from cholera with high temperature the red corpuscles are often actually distorted in the circulating blood, but in suitable preparations they should show no fine crenation, this being the indication of a defect in technique.

Films for staining were spread on slides after the usual manner with the edge of another slide, or more satisfactorily, because thinner spreads are more uniformly obtained, with the clean and straight edge of a piece of an ordinary business card.

Citrated blood always shows fine crenations and other changes in the erithrocytes when seen with the high power objective and such preparations are useless for either fresh or stained specimens.

In examining fresh vaseline sealed preparations, illumination by daylight is insufficient. I have used a large Mazda incandescent lamp along with a globe condenser. The best lenses are of course desirable. Zeiss apochromatic 2 mm. and 1.5 mm. objectives and compensating oculars Nos. 6 and 8 have been used in my work. For dark field work with blood cells I have found the small arc lamp supplied with these outfits less satisfactory than a large Mazda lamp and globe condenser. This light is hardly sufficient, but it is steady and gives a clearer picture than the unsteady, flickering arc lamp.

There is, in our language at least, very little published on the hematology of the domestic animals. Burnett in "Clinical Pathology of the Blood of Animals" gives a list of red and white cell counts and differential leucocyte counts of various species using the classification customary for human leucocytes. There is, however, a difficulty in referring many of the leucocytes of pigs' blood to the classes met with in human blood. This will be discussed later when considering stained preparations.

In fresh blood slides prepared as above, the erithrocytes of pigs' blood show in an extreme degree certain phenomena which have been

described by other writers as occasionally occurring in human blood when subjected to overheating during the preparation of the specimen.* These are described and illustrated by Balfour under the title "Fallacies and Puzzles in Blood Examination,"† but are entirely missing from the text books dealing with hematology in use in this country. I infer from this, as well as from my own observation, that the blood of pigs is unusually prone to undergo such changes.

To one observing this phenomenon for the first time the picture is surprising. Whip-like quivering and exceedingly tenuous filaments which by the highest powers and by close focusing can be seen to be

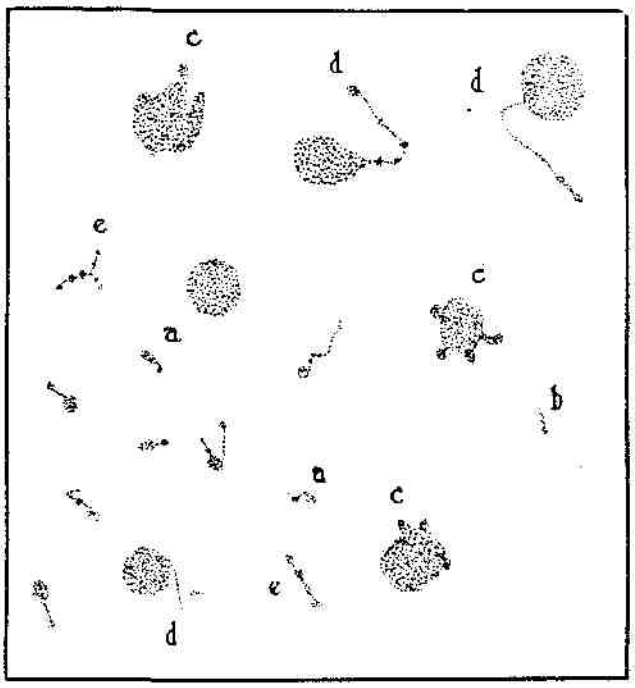

PLATE I.

Extracellular bodies and offshoots from erithrocytes. (*a*) Common form, possibly a blood plate. (*b*) A dumbbell shape, also common in pigs' blood. (*c*) Bud-like processes from erithrocytes. (*d*) Filamentous offshoots. (*e*) Probably detached filaments.

attached at one end to the erithrocytes, longer and shorter bead-like chains, either free or attached, and bud-like projections from the more or less distorted red cells are the most striking features observed. There are also smaller free bodies of various shapes all in quivering motion and apparently also offshoots from the red corpuscles. Plate I, shows the variety of forms which may be observed.

These are not seen in all specimens. They occur in normal and in cholera infected blood. They may be seen within an hour after the blood is collected, but are more frequently observed several hours after

*Buchanan: The Blood in Health and Disease.
†Fourth Report, Wellcome Laboratories.

collection. Figures a and b are forms which seem to be always present in pigs' blood thus prepared for examination. Whether these also are offshoots from the red corpuscles may be questioned. The larger form (Fig. a) may represent a blood platelet.

Most of the smaller granules, those seen in examination with dark field illumination, I believe to be derived by further breaking up of these castoff outshoots from the red corpuscles.

This is obviously not a phenomenon of infection nor of fevered blood, since the most extreme pictures of this kind have been seen in the blood of normal or non-infected pigs.

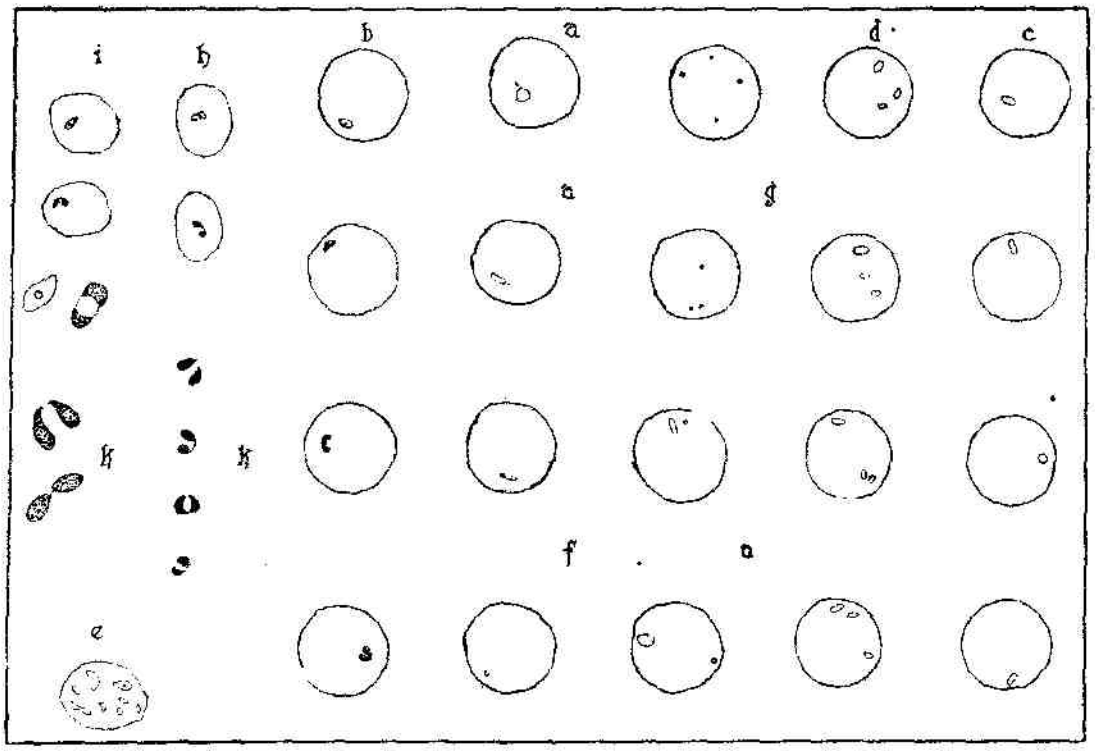

PLATE II.

Endoglobular motile bodies, showing changes of outline and of position in cell. (*a*) Disk shape and minute speck. (*b*, *h*, *i*) Horse shoe or crescentic form. (*k*) Same showing outlines exhibited during movements. (*e*) Small erithrocyte showing numerous motile bodies. (*c*, *d*) *Oval forms showing locomotion (vertical reading).*

Blood collected in 2 per cent sodium citrate solution always shows numerous fine quivering dentritic processes around the margin of the erithrocytes.

Most specimens of pigs' blood properly collected and sealed between slide and cover do not show the phenomena above described to any extent, if at all, for many hours after collection. They are not due to heating the specimen, at least not in my preparations, but result probably from irritation of the cell protoplasm by chemical changes incident to beginning loss of vitality.

Endoglobular phenomena. A more common feature of pigs' blood when thus examined and one which distinguishes it from the blood of any other animal species with which I am familiar is the occurrence in practically all specimens within the area of the red cell of refringent motile bodies which, with the highest magnification, show a certain degree of uniformity in shape. These are apparently intracellular. Their focus corresponds with the margin of the cell or, in their motion, may alternately be slightly above or below the focus, but their migrations never carry them beyond the margin of the cell. They may be observed with direct or dark field illumination. Much time has been devoted to the study of these bodies because, although they also occur and were first observed in normal pigs' blood, it was found that they were usually much increased in number in the blood of cholera infected hogs and it was thought that they might be a diagnostic feature of this disease.

In a comparative study of the blood of other animals—horses, cattle, sheep, rabbits and guinea pigs, as well as human blood, I have seen nothing which corresponds at all with these motile bodies within the corpuscles of pigs' blood. Very rarely in other animals one may see within the area of the disk very minute granules, usually single, which show a migratory motion across the cell. I have observed this in the blood of the sheep and rabbit. Th. Smith in his monograph on Texas Fever describes a similar phenomenon in the erithrocytes of cattle blood (p. 56). These may be compared to the very smallest forms, traveling specks, which are common in the erithrocytes of the blood of pigs, but, except in the matter of motility, they have little in common with the relatively large and distinctively formed objects seen in Plate II.

Omitting the smallest bodies too minute to allow recognition of their shape these bodies occur in three distinct forms: (1) as round or short oval slightly biconcave flattened disks; (2) as long oval or rice grain like bodies; (3) as crescentic or horse shoe like forms. All of these forms may be found in the same blood sample. Usually the disk form is most abundant. It also exhibits the most active motility and the greatest diversity in size. In the blood of non-infected pigs these bodies are scarce, but may be found by careful search in nearly all specimens. None of the forms mentioned are characteristic of cholera infected blood, but their number in such blood is often largely increased. Although this is the rule, there are cases of cholera infection in which I have failed to find any increase.

The *disk* shape (Fig. a) varies in size from about one-fourth the

diameter of the cell downwards, the most common size being about one-eighth. They are fairly refringent and appear either with circular outline or as a rod shape according as seen on face or on edge. This change in outline which is accompanied by locomotion—change of position in the cell—may be readily followed by continuous observation under the microscope for a few minutes or even at times for one minute or less. Motion is inhibited by cold, but not by ordinary room temperature (70° F. or up). In the crescentic or horse shoe forms motion is more sluggish, but usually quite appreciable. (Fig. b.)

The motility and change of outline of these bodies can be most readily appreciated by a study of the drawings on Plate II.

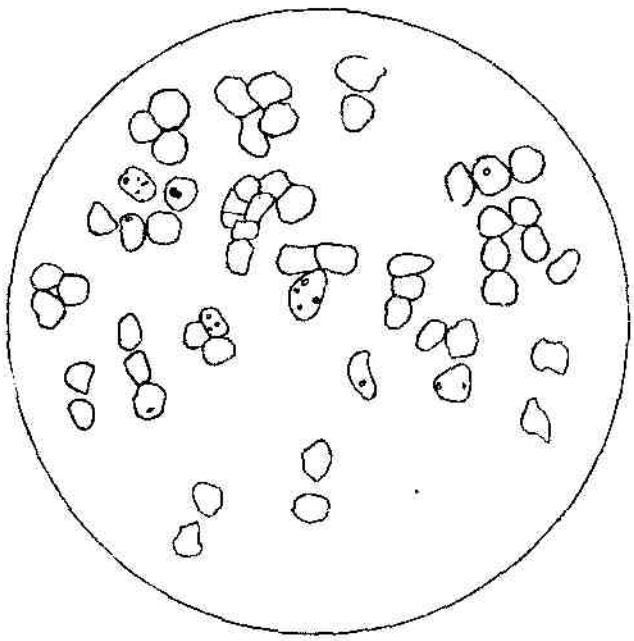

PLATE III.
Specimen of cholera infected blood showing numerous endoglobular motile bodies; (*camera lucida tracing*).

The erithrocytes in which these bodies occur may be of normal size or slightly larger or smaller than the average and are not commonly otherwise distorted. Most frequently they occur singly in the cell, but doubles are nearly as common and six or eight may be found. Those cells which carry such numbers are generally smaller than the average and I have only found them in cholera infected blood. (Fig. e.)

With the dark field condenser they appear when in focus as silvery shining solid objects or as tenuous undulating rings (the outlines only showing the light reflection) rising and falling in the discoplasm and migrating by a creeping or undulatory motion across the cell. They

may be observed for several days after preparation of the slide without undergoing any appreciable change.

Besides these more characteristic forms minute rod shaped bodies are also found which, although actively motile, never show the disk outline. They appear only as rods or as round points when seen on end. (Fig. f.) Traveling specks or granules are frequently seen either singly or in number up to three or four and quite generally associated with larger forms in the same cell. (Fig. g.)

The cells in which these motile bodies occur are not obviously deficient in hemoglobin so far as can be seen in unstained preparations. In some preparations pale or washed out looking erithrocytes may be seen in which rounded non-motile objects are present. These present a different appearance from the motile objects just described in their refringency and lack of motility and are apparently vacuoles.

The motility of these endoglobular bodies is of course not to be compared with that of bacteria, nor can it be properly described as ameboid, nor yet as molecular. It differs from molecular motion in the slowness and greater range of oscillation, characters which are easily apparent by comparison with the extracellular granules which may be seen in the same field. From ameboid motion it differs in the absence of any observable actual change of shape, the difference in outline as figured being due to the particular angle at which the object is seen in its turning movements. With the dark field, however, the largest of these bodies show a close similarity to an ameboid form of motion.

Between the cells in pigs' blood and more numerously in infected blood, a variety of minute quivering or dancing bodies may be seen, the origin and nature of which I do not know. Some of these show a certain uniformity in shape as seen in Plate I, a, and may be offshoots from the erithrocytes such as previously mentioned. The great mass of granules brought to light with the dark field condenser are invisible by direct illumination. I have not been able to observe any connection between these intercellular objects and those seen within the corpuscles. The dumbbell shape (Pl. I, b) which exhibits exceedingly active dancing motion (molecular?) is one of the most frequently observed of these intercellular bodies. This object, however, may also be observed in normal human blood. It shows little refringency and is only to be seen with the best illumination.

With the dark field many more intercellular granules are brought into view than by the open condenser. These are increased in number some hours after collection, probably by casting off and breaking

up of processes from the erithrocytes in the manner already described. In diseased blood (cholera infected) the intercellular or plasma granules are usually more numerous than in normal blood. In all pigs' blood they are greatly more numerous than in the blood of man. They exhibit the greatest diversity of shape and size, but I have seen no form which could be regarded as characteristic of cholera infected blood. Spirochaete which have been found by King* in citrated blood of hog cholera I have not seen or, at least, have been unable to recognize as such in the few specimens so far examined specially with this end in view.

Stained preparations. Naturally many more samples of blood have been examined in stained preparations than could possibly be examined in the fresh condition. I have, however, found the time to stain and examine only a small part of the many hundred smears made from cholera infected hogs, this, like many others, being a task which could not be deputed to any available laboratory assistant. As far as possible I have endeavored to examine in stained films samples of blood which had on the date of collection likewise been examined in the fresh or unstained condition in order that the nature of the bodies above described might be further elucidated by their reaction to the stain.

Films were stained by all the ordinary stains used in blood work—Giemsa, one solution stain after fixing with methyl alcohol, Jenner, Leishman and Wright's modification without fixation, eosin and methylene blue and hematoxylin and eosin with various methods of fixation. Most of the staining was done by the Giemsa, which brings to view anything brought out by any of the other stains and usually gives a cleaner slide than the other Romanowsky stains, that is, one freer from precipitate.

To one accustomed to blood examinations the feature which first attracts attention in pigs' blood is the presence of small, round, solidly stained bodies within the erithrocytes. In some specimens these are sufficiently numerous to be observed in every field. There may be as many as six or eight to a field, but in most samples of normal blood they do not exceed an average of one to the field, that is, something less than one-half per cent. These bodies are single, nearly always eccentrically placed, though not usually quite marginal in position, and vary in size from small to large cocci. Indeed, they bear a close resemblance to isolated micrococci in shape and reaction to stains. They are practically always single in the cell. Diplococcoid or

*Journal Inf. Diseases, Vol. 12, No. 2.

cleavage forms have been seen, but they are extremely rare. (Pl. V, e.) These double forms apparently represent an incipient process of division, although a complete separation into two objects has never been observed. In some specimens exactly similar extracellular bodies may be seen, giving the impression that they had been extruded from the corpuscle, a view which is further favored by the occasional occurrence of bodies on the extreme margin of the cell. (Pl. V, b.)

Between these intracellular coccoids and the nuclei of the erith-

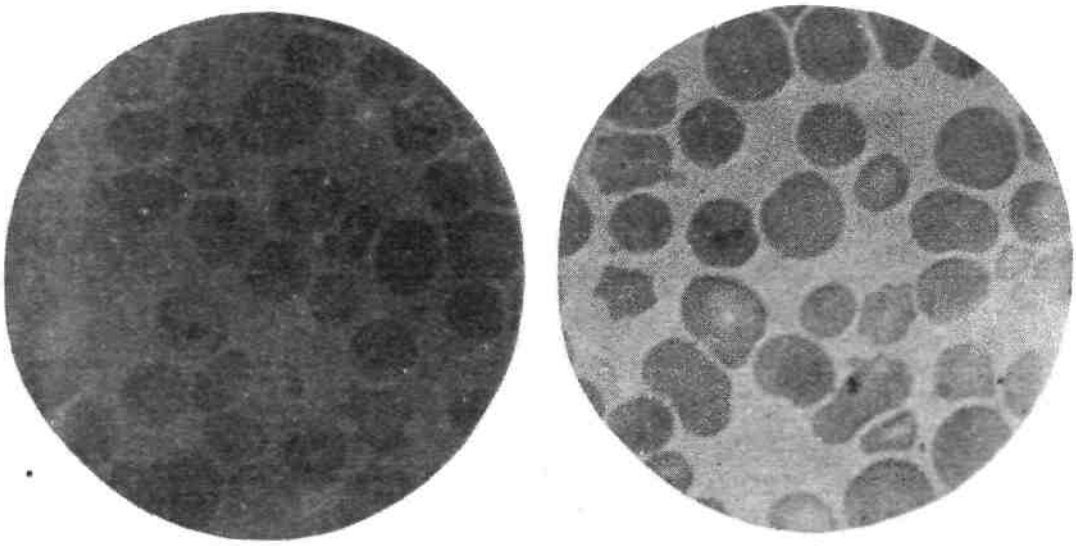

A. B.

PLATE IV.
Photomicrographs showing coccoid bodies. (*a*) Cholera infected blood. (*b*) From an anemic pig, non-infected.

roblasts there is no apparent relation except in their basophilic reaction to stains. They show no reticulation or differentiation of structure except that with faint staining (Leishman) the periphery is more deeply colored than the central area. With methylene blue or Jenner's stain they are colored blue, with Giemsa a dark ruby red. As to the erithrocytes in which they occur they are, with the exception to be noted, not otherwise abnormal. In the blood of some infected animals in which marked anisocytosis was present with diminished red cell count, most of these bodies would be found within enlarged cells (megalocytes) with deficient hemoglobin. In the same preparation, however, bodies would be seen within microcytes or cells of normal size. Unusual numbers of these bodies in any specimen was found quite generally associated with such abnormalities in the erithrocytes. (Pl. IV, a, b.)

Erithroblasts may be found in preparations from the blood of normal or non-infected pigs. They are often more abundant in the

blood of cholera infected animals especially at a late stage of a chronic form of the disease, but are never sufficiently abundant to form a feature of cholera infection. As already stated intracellular coccoid bodies are as a rule quite markedly increased in number after infection. (Table II.) This, however, is not invariably the case, nor is there any uniform correspondence between the increase in the number of these intracellular coccoids and the number of erithroblasts present. That they are in some way dependent upon or, at least, associated with conditions which give rise to malnutrition and anemia seems probable from a study of Table II, in which it will be seen that their increase, when marked, corresponds with a diminution in number of red cells. It also coincides, as has been said, with the presence of macrocytes and microcytes and with deficient hemoglobin content. In these specimens the bodies are found generally within such altered corpuscles and they show a greater variation in size than in normal blood.

In young animals they appear to be more abundant than in older, although they have been found in full grown serum hogs in considerable number.

An interesting observation which I have so far had no opportunity to duplicate was made on examining the blood of four or five weeks old suckling pigs farrowed by a sow which had been hyperimmunized for the production of antiserum. The three survivors of this litter, although rather small, were apparently in a healthy condition, but the blood examination showed an anemia especially marked in one (the largest and fattest of the three). In all of these the intracorpuscular bodies were unusually abundant, varied much in size from minute points almost up to the average size of the nucleus of a normoblast, and in the most abnormal specimen of the three they were present sometimes in twos or threes within the same corpuscle. The blood of this pig, thin and watery looking to the naked eye, contained only two million reds to the c. mm. and these showed all abnormalities seen in the blood of a primary anemia. In the other two the anemia was less pronounced (Table I, Nos. 15, 16), but the histological abnormality of the erithrocytes quite evident. In these cases the excessive number of intracorpuscular bodies coincided with an excess of erithroblasts. Occasionally one would be seen of such size that it was scarcely distinguishable from the nucleus of a nucleated red. Besides the bodies which correspond in size with those seen in normal pigs' blood the blood cells of this animal showed numerous smaller but otherwise similar granules, giving the picture known as baso-

philic granulation. Polychrome cells were also abundant. (Plate IV, b.)

The interest in this case lies in the possible clue which it furnishes as to the derivation of those intracellular coccoids. Here these coccoids were present in unusual numbers occasionally multiple in the cell and exhibited all gradations in size from nearly that of a normoblastic nucleus down to minute granules. This was accompanied with a marked oligocythemia, poikilocytosis and excess of erithroblasts. But the majority of the coccoid bodies were solitary and otherwise identical in appearance with those seen in normal blood. It may be inferred, therefore, that the excessive number of coccoids in this



PLATE V.

Intracorpuscular coccoids or Jolly bodies (?) in Giemsa stained preparations (composite). (*a*) Normal pigs' blood. (*b*, *c*, *d*, *e*) Infected blood. (*b*) Shows megalocytes with deficient hemoglobin. (*c*) A normoblast. (*d*) Extracellular body. (*e*) A double form.

case was due to the exaggerated or pathologic operation of the same influence which gives rise to their occurrence in moderate numbers in normal blood.

Nature of coccoid bodies. Although at first inclined to look on these coccoids as the stained representatives of the motile intracorpuscular bodies seen in fresh specimens, it was soon found that this view was untenable. These latter are often multiple in the cell and variable in shape, while the stained bodies are always round in outline and practically always solitary in the cell. They may also be rare in specimens in which the unstained objects are numerous. These latter also, so far as I have been able to discover by prolonged trial, do not

stain at all or only very feebly and may be seen in some stained specimens as unstained objects. The round or coccoid bodies take the chromatin stain as deeply as the nucleus of a red cell.

As we have seen, they can not be regarded as features of cholera infection, since they occur in non-infected animals as well as infected. They correspond closely to the description and figures of Theiler's anaplasma infection of cattle in the disease known as "gall sickness" in South Africa.

Similar bodies have been described by Balfour as occurring in the blood of a donkey in the Sudan and on this finding he bases his "Notes on Anaplasmosis of the donkey."*

Gilruth notes their occurrence in the blood of several animal species native to Australia† and includes the pig in his list, which is the only record I have found referring to their occurrence in this species.

A further review of the subject is given by Dodd.‡

In all these reports the question of the identity of these bodies with the *Anaplasma marginale* of Theiler or with the nuclear structures known as Jolly bodies remains in doubt. Jolly bodies or Howell-Jolly bodies are said to occur in human blood under certain pathologic conditions and in rodents as an apparently normal structure. Bodies indistinguishable from those above described as occurring in pigs I have seen in two other animal species—in preparations from the blood of a cat affected with rabies in which they are fairly numerous (and associated with anisocytosis) and in smears from angiomatous areas in the liver of cattle, in which they are rare but quite typical. They may occur in other animal species, but in the domesticated animals other than the pig they must be rare, since in routine laboratory work they have not been observed.

As to the nature of these bodies in pigs' blood, I have regarded them as nuclear structures and identical with the Jolly bodies of other writers. There seems to be no sufficient grounds for supposing them to be parasitic in nature. Their occurrence in all animals of this species§ precludes the possibility of learning anything as to their parasitic nature or otherwise by inoculation experiments to hogs. Several attempts have been made to transfer these bodies to the guinea pig by inoculation of blood from pigs in which they were abundant, always with negative result. Their increase in number in conditions of

*Fourth Report, Wellcome Laboratories.
†Parasitology, Vol. IV, No. 1.
‡Jour. Comp. Pathology, Vol. XXVI, Part 2.
§My observations cover specimens from hogs in northwest Arkansas in the neighborhood of the laboratory, from southern and central Arkansas and from Oklahoma, Kansas and Missouri, at the public abattoir and packing house in Little Rock.

anemia, in which there is a tendency to the appearance of erithroblasts in the blood, favors the view that these also are remnants of nuclei of bone marrow erithroblasts which in pigs enter the circulation in small number under normal conditions and in increased number in the toxemic anemia which may accompany cholera infection. This opinion, however, may be modified by further investigation.

Ring forms in cholera infection. In a small percentage of cases of acute hog cholera blood films treated with Giemsa or Wright's stain have shown the peculiar structures illustrated in Plate VI. These are irregular ring shapes looking as if plastered over the surface of the red cells, some projecting beyond the margin and even lying intercellular. It is only in a few blood samples that they have been seen so numerous as in the figure, but in many others they have been found in small number by careful search. In these latter they are usually limited to the area of the cell, to the surface of which they seem to be applied. The rings are colored by the nuclear staining component of the stain various shades of purple to red. As already said, these ring forms are apparently absent or so rare as to escape observation in most samples of cholera blood, but in some cases they are exceedingly numerous. They appear in all preparations made from the same blood sample and are absent from others similarly treated for comparison, hence are attributable to the condition of the blood and not to defect in staining as I was at first inclined to think. They bear little resemblance to the rings of Schleip or Cabot and can hardly be confounded with the various deceptive appearances produced by precipitates from the staining fluid.

Such forms have never been seen by me in blood preparations from uninfected animals, but they have not been sufficiently studied to allow of the suggestion that they are characteristic of cholera. It is possible that these ring forms may be due to some alteration in the blood cells which gives rise to a deposition of the stain in this peculiar manner. It may also be conceivable that they are the stained representatives of the endoglobular bodies seen in fresh preparations. Against this latter view are the facts that they may be found beyond the area of the blood cells and in some preparations occur in much greater number than any bodies that can be found in unstained wet specimens. Also, the most characteristic form of these endoglobular bodies does not appear in the stained slide. This is the horse shoe, crescentic, or bipyriform shape. (As may be seen in Pl. II, Figs. b, h, the same object may appear in each of these shapes according to the view that is presented in its movements.)

The ring forms, but for the fact that they bear no resemblance to bacteria either in staining or shape, might be regarded as one of the mixed bacterial infections which are common in hog cholera. My present opinion is that they are foreign organisms of some kind, if not bacterial, probably protozoal.

The intracorpuscular motile objects described earlier in this report I have attempted to compare with the figures and descriptions of the phenomena ascribed to endoglobular degeneration, of which, however, the available literature in English is extremely scanty. "Maraglia-

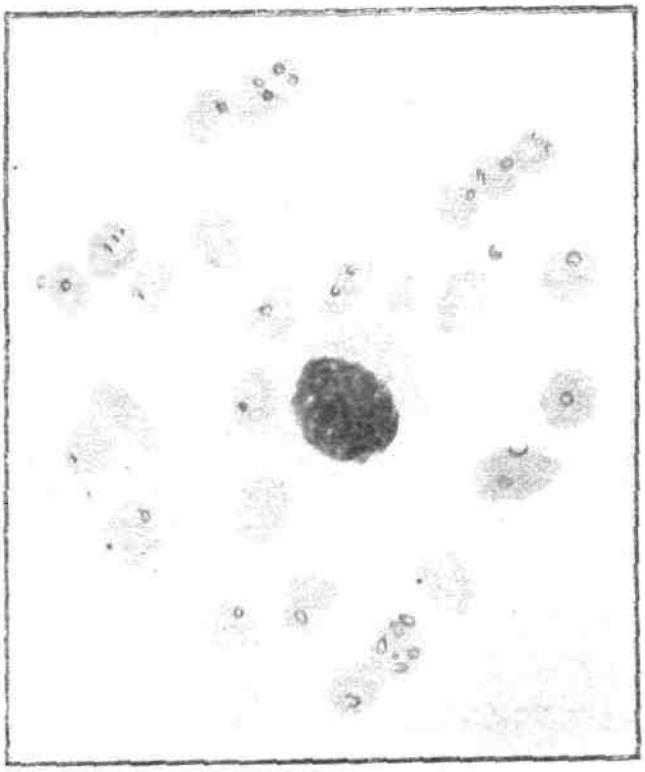

PLATE VI.
Giemsa stain of infected blood showing numerous ring forms. (*Camera lucida tracing.*)

nos" are described as motile bodies which may be confounded with piroplasms in fresh preparations. It will be noticed (Pl. II, Figs. h, i, k) that the horse shoe shaped body I have described may in certain positions show a quite distinct bipyriform shape. This is the most characteristic in shape of the various forms described, but does not apparently differ from the disk forms other than in shape. It has not been well identified in stained slides, although in some of these unstained objects looking like vacuoles may be seen which show a similar outline. These latter, however, may be quite numerous in certain areas of the slide and absent in others, which indicates that they are due to uneven

fixation or drying, perhaps vacuoles from shrinking of the cell contents.

That the motile bodies occurring in the wet preparations may have a similar origin or result from changes in the cytoplasm such as appear to occasion the extracellular or filamentous offshoots earlier described is at least a conceivable explanation. The dubious results obtained in staining these bodies is an argument against the view that they are foreign organisms, but when examined in fresh blood it is difficult to divest oneself of the impression that they are actually of this nature. At any rate this phenomenon of endoglobular degeneration (if it be such) is one which in the blood of pigs seems to be mani-

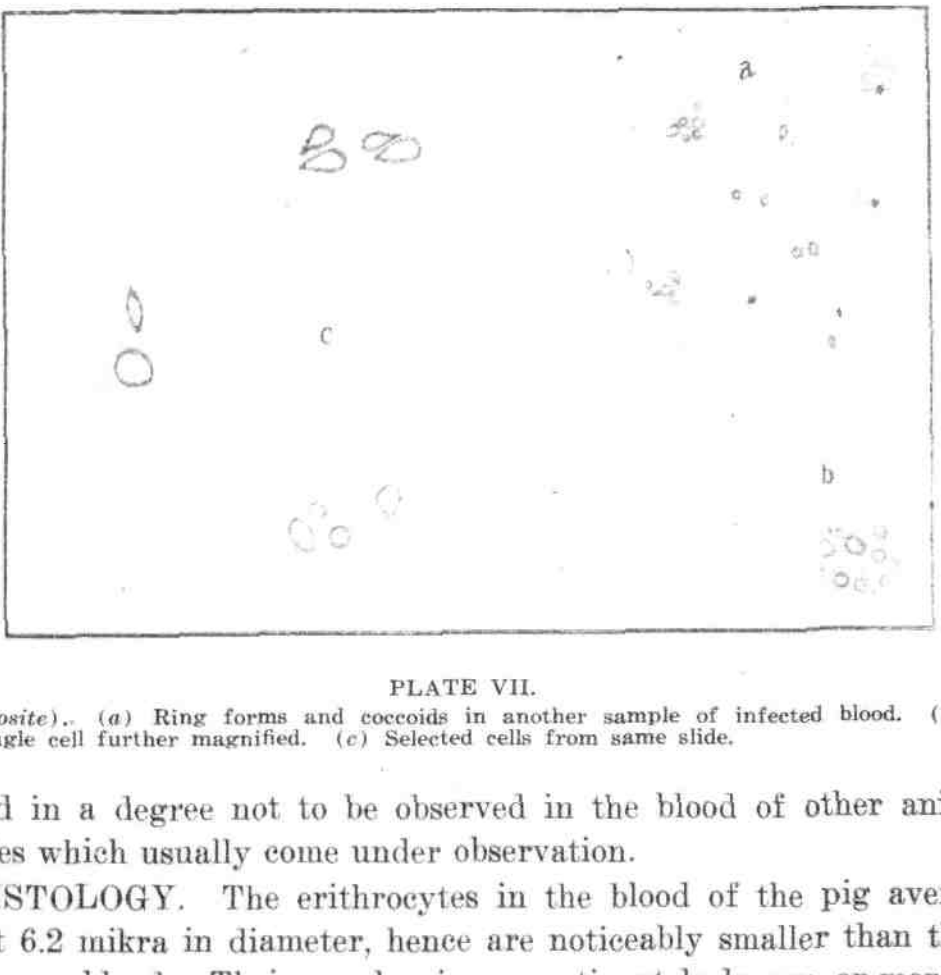

PLATE VII.

(*composite*). (*a*) Ring forms and coccoids in another sample of infected blood. (*b*) A single cell further magnified. (*c*) Selected cells from same slide.

fested in a degree not to be observed in the blood of other animal species which usually come under observation.

HISTOLOGY. The erithrocytes in the blood of the pig average about 6.2 mikra in diameter, hence are noticeably smaller than those of human blood. Their number is proportionately larger, or more so, averaging from 7 to 9 million per c. mm. The number, as can be seen from Table I, varies considerably in apparently healthy animals. Occasional normoblasts occur, in young pigs especially. As has been already said, Jolly bodies (or what I take to be such) are uniformly present in number, averaging somewhat less than one-half per cent of the total number of corpuscles.

The leucocytes, as might be expected, vary in number even more than the reds. Their average seems to be from seven to ten thousand per cubic millimeter. (Table I.)

Lymphocytes are normally in much larger proportion than polymorphs. Small lymphocytes (approximating in size that of erithrocytes) are rare, most of them being twice that size or more. There is no plain distinction to be made between the larger lymphocytes and the large mononuclears as commonly figured and described. Indented and irregular shaped nuclei are common. This is especially the case in infected blood.

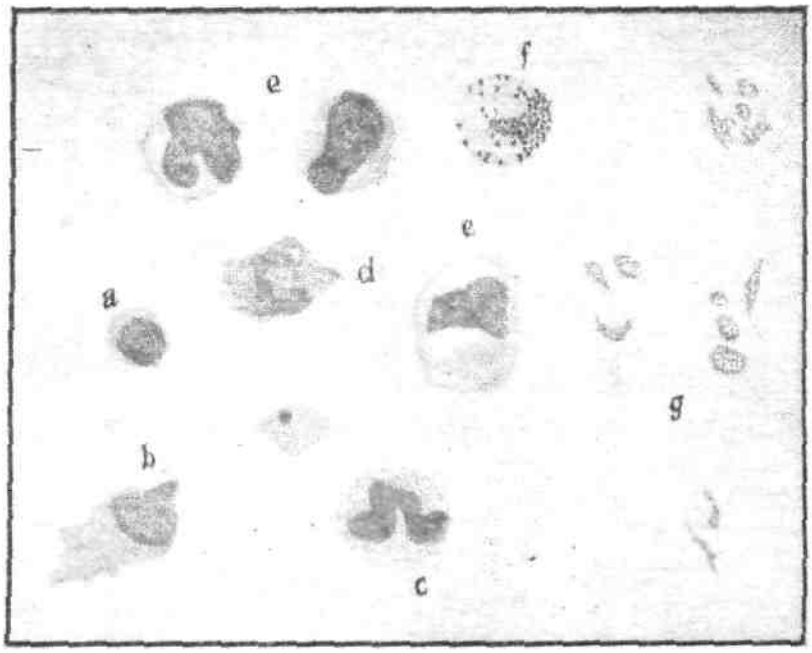

PLATE VIII.

Showing forms of leucocytes in infected blood. (*a*) Small lymphocyte. (*b*) Larger lymphocyte, probably distorted by pressure. (*c*) Polymorphonuclear leucocyte. (*d*) Transitional. (*e*) Mononuclear cells. (*f*) Basophile. (*g*) Blood platelets.

Polymorphs do not show a distinct granulation, but the cytoplasm takes a pinkish color, in which fine granules may be detected in over fixed specimens.

Eosinophiles show no unusual features. Basophiles (polymorphonuclear cells with basophilic granules) may be found in most samples, sometimes equaling the eosinophiles in number.

In the table showing differential counts, lymphocytes are not given in two classes, large and small, since any such separation would be an entirely artificial one. In pigs' blood, while typical small lymphocytes occur, they are few in number, the great majority being larger than this and ranging up to two or three times the size of the smallest.

They also possess an extremely variable amount of cytoplasm around the nucleus.

In pathologic blood (hog cholera infection) the difficulty of classifying these mononucleated cells is increased on account of the number of atypical forms. Large mononuclear cells are not always to be distinguished from the largest lymphocytes, nor are transitionals always to be clearly separated from polymorphs. The classification given in the tables, however, is probably as nearly exact as are most leucocyte counts. In these tables mononucleated cells are all grouped in one class; transitionals are so numerous in some specimens that this group could not well be merged with polymorphs or mononuclears.

Table I shows the red cell count in three to five months old pigs to vary between six and a half and nine millions. An average (if one can get an average from four counts only) would be about 7,500,000 per cubic millimeter.

The white cell count apparently may be as low as 7,000. The normal high limit or the average can not be accurately reckoned from this data since the variation is so great, but the average may be approximately placed at ten to twelve thousand. Since many pathologic conditions in hogs are found at slaughter which may increase the leucocyte count and yet in life produce no symptoms, the normal upper limit would be difficult to arrive at. The differential count is influenced by the same factors and the percentage, of course, dependent upon the total count, hence the data furnished by the tables are to be considered as approximate.

In uninfected pigs the mononuclear cells greatly outnumber the polynuclear. The average of the ten percentage differential counts in Table I (excluding six, which were obviously abnormal) gives a ratio of two mononuclears to one polymorphonuclear. The mononuclears in normal blood are nearly all lymphocytes, mostly of the large variety. They show great variation in size, in shape of nucleus and in relative amount of cytoplasm. Transitionals, those with a more or less irregular nucleus and discernible tendency of the cytoplasm to take the eosin stain rather than the blue, average two to three per cent. Eosinophiles average four to five per cent according to the table, with a range of from less than one per cent up to ten. The Jolly bodies (if they are such), listed as coccoids in the table, represent the numbers which were observed in the differential leucocyte count per 100 leucocytes. They give an approximation of the relative numbers in the different samples. The actual numbers are considerably larger, since many would be overlooked in the rapid work

of leucocyte enumeration. These figures, of course, have no relation to the percentage of erithrocytes containing Jolly bodies. This I have estimated at something less than one-half per cent, as an average.

In cholera infected hogs the most obvious change is a leucopenia, which is usually demonstrable on the first appearance of sickness. This is so marked that one readily notices the scarcity of leucocytes in examining stained blood slides, even when no count has been made. Along with this there is an increase in the relative number of atypical large mononuclear cells and transitionals and a diminution in the more typical lymphocytes. The relative proportion of mononuclears and polymorphs is changed, but without uniformity. Sometimes there is a great relative diminution in number of the polymorph cells, with an increase in transitionals or immature neutrophiles. In others there is a large polymorph leucocytosis, which is due to some inflammatory complication, commonly pneumonia and pleurisy. In the later stages of these cases the polymorph leucocytosis may disappear. (Cases 2, 4, 9, of Table II.)

The erithrocytes in cholera infection undergo a moderately rapid diminution in number up to a certain stage, but extreme oligocythemia is not a feature of this disease. Numbers up to four or five million may be found at death, and even in prolonged chronic cases the number may be found much larger than the condition of the animal would indicate.

Erithroblasts, which are found in small number in normal blood, generally undergo a moderate increase after cholera infection, especially if the case is prolonged. As may be seen from the tables, the intracorpuscular coccoids show a distinct though far from uniform increase.

Table I. Blood counts in normal or uninfected pigs. Age, 3 to 5 months.*

No.	No. per c. mm.		Differential leucocyte count; %.					Per 100 leucocytes.		Remarks.
	Reds.	Whites.	Mononuc.	Polym.	Trans.	Eosin.	Baso.	Nuc. reds.	Coccoids.	
1	....	......	75	24	..	1	..	..	..	....
1	....	......	68	25	..	6	1	2	11	2d count, 1 month later.
2	....	......	46	52	1	1	..	..	..	Pustular eruption on skin.
3	....	......	57	32	1	10	..	..	..	....
4	....	......	38	56	4	..	2	..	7	Abscess in parotid region.
5	7,100,000	17,600	58	40	1	..	1	1	14	....
6	6,600,000	7,000	..	..	..	..	..	..	..	No differential count.
7	....	......	55	36	6	2	1	..	7	....
8	....	......	66	26	3	3	1	..	4	....
9	....	......	48	38	5	9	..	..	8	....
10	....	......	62	27	..	10	1	..	1	....
11	....	......	62	32	3	3	..	..	..	....
12	9,000,000	8,000	65	28	6	1	1	1	2	....
13	7,800,000	16,000	24	75	1	..	..	..	10	Small, unthrifty pig.
*14	2,090,000	13,000	81	16	3	..	..	10	222	Suckling of serum hog.
15	6,300,000	13,500	77	20	1	2	..	6	175	Suckling of serum hog.
16	5,450,000	7,800	59	38	2	1	..	21	140	Suckling of serum hog.

*Nos. 14, 15, 16 showed marked poikilocytosis, polychromasia and punctate basophilia; coccoids mainly in large pale or in small shrunken cells.

Table II. Blood counts in cholera infected hogs. Age, 4 to 5 months.

No.	No. per c. mm.		Differential leucocyte count; %.					Per 100 leucocytes.		Remarks.
	Reds.	Whites.	Mononuc.	Polym.	Trans.	Eosin.	Baso.	Nuc. reds.	Coccoids.	
1	....	......	56	38	5	..	1	..	6	Early stage, natural infection.
2	....	......	74	12	14	..	..	..	40	Just before death.
3	4,800,000	6,000	48	51	1	..	..	..	176	Six weeks; chronic.
4	....	......	72	6	16	..	..	..	28	Ninth day.
5	6,300,000	4,600	59	34	7	..	..	3	40	2d day of sickness.
6	2,500,000	8,700	64	19	15	..	2	..	7	Two weeks after inoculation.
7	....	......	50	41	9	..	..	2	75	Two weeks after inoculation.
8	....	......	62	27	1	10	..	..	2	Before infection.
8	....	......	48	39	6	7	..	1	9	5 days after infection.
8	....	......	66	25	..	8	1	5	40	7 days after infection.
8	....	......	63	29	6	..	2	..	10	16 days after infection.
8	5,000,000	1,800	68	30	..	..	2	..	24	20 days after infection.
9	5,200,000	5,800	..	..	..	..	..	..	..	No. dif. count. Sick 4 days.
9	....	......	62	29	8	..	1	1	45	5th day; very atypical leucocytes.
9	....	......	30	54	14	2	1	..	..	14th day; leucocytosis.
9	3,700,000	15,300	20	65	10	5	..	..	20	18th day; lived two weeks longer.
10	6,800,000	2,000	55	40	2	1	2	..	23	6th day of sickness.
10	5,700,000	2,600	78	19	1	2	..	..	8	12th day; chronic.
10	4,100,000	2,200	80	19	..	..	1	2	6	15th day.
10	4,600,000	3,300	67	32	..	..	1	3	9	18th day; recovered.
11	6,900,000	16,500	59	30	2	9	..	..	5	Before infection.
11	6,736,000	5,300	59	21	6	1	..	2	8	3d day of sickness.
12	7,100,000	8,500	21	72	6	1	..	8	14	1st day of sickness.
12	6,200,000	6,400	27	68	4	..	1	6	15	4th day.
13	6,400,000	4,600	59	34	7	..	..	..	40	2d day of sickness.

SUMMARY. In the course of a somewhat prolonged study of the blood of pigs, normal and cholera infected, certain peculiarities of the erithrocytes were observed, some of which seem to have hitherto escaped observation or to have passed unrecorded. These, mentioned in the order in which they are more fully described in the text, are:

(1) The high susceptibility of these corpuscles (when examined in fresh preparations) to throw out from their margins processes from the cytoplasm in the form of buds, filaments or strings of beads, some of which become detached and occur in the plasma as active bodies of various bizarre forms. These, in part, form the plasma granules seen by dark field illumination. This phenomenon occurs in normal and infected blood.

(2) The occurrence within the red corpuscles of motile bodies of a certain uniformity of shape often present in large numbers in infected blood and dubiously referable to the phenomenon of endoglobular degeneration of Maragliano and others.

(3) The uniform presence in the red corpuscles of pigs (after Romanowsky staining) of solitary coccus-like bodies, usually eccentric in position, occasionally marginal. These bear a close resemblance to the figures of Theiler's *anaplasma,* the reputed cause of "gall sickness" of South African cattle. They are also similar, and I believe identical, with the Howell-Jolly bodies of other writers. They seem to be a normal feature of the blood of hogs and their increase in number in infected blood is associated with a coincident anisocytosis and anemia. I regard them as nuclear remnants.

(4) The occurrence in Romanowsky stained films of infected blood of peculiar ring-shaped bodies, which appear to be attached to the surface of the red corpuscles. These are sometimes found in large numbers, though not constantly present, and their nature and possible relation to hog cholera infection remains undetermined.

(5) Hog cholera infection gives rise at an early stage to a pronounced leucopenia, with the appearance of numerous atypical mononuclear or transitional leucocytes. When inflammatory complications occur a polymorph leucocytosis appears. The destruction of red corpuscles is not a prominent feature of the disease.